



Comparative effect of the incorporation of *Moringa oleifera* and *Carica papaya* leaf powder into diet on coccidiosis and growth in rabbits in Burkina Faso

Barkwendé Jethro Delma¹, Alice Gisèle Sidibé-Anago¹, Gildas Marie Louis Yoda¹, Jean Sawadogo², Valérie Marie Christiane Bougouma²

¹Institut de l'Environnement et de Recherches Agricoles (INERA)/Centre National de Recherche Scientifique et Technologique (CNRST), 04 BP 8645 Ouagadougou 04 Burkina Faso

²Université NAZI Boni (UNB), 01 BP 1091 Bobo-Dioulasso 01 Burkina Faso

Corresponding Author: delmabjethro@yahoo.fr

Submitted 12/10/2025, Published online on 31/12/2025 in the <https://www.m.elewa.org/journals/journal-of-applied-biosciences-about-jab/> <https://doi.org/10.35759/JABs.215.2>

ABSTRACT

Objective: This study compared the effects of incorporating *Moringa oleifera* (Moringa) and *Carica papaya* (Papaya) leaf powders into rabbit feed on their growth and coccidiosis control in Burkina Faso.

Methodology and Results: The study was conducted at the Animal Production and Health Research Laboratory of the Saria Research Station. The study involved 28 weaned rabbits divided into seven groups, each receiving different rations with varying percentages of *Moringa oleifera* and *Carica papaya* leaf powder (5%, 10%, and 15%). The study revealed a significant reduction in the excretion of coccidiosis oocysts in rabbits fed *Moringa oleifera* (750 ± 687.38) and *Carica papaya* (16.667 ± 28.87) leaf powder compared to the control group (6300 ± 2338.8). The incorporation of moringa and papaya leaf powders had no negative effect on the weight gain of rabbits. The group fed 15% Moringa showed the highest weight gain (751 ± 206.93 g), indicating a positive impact on growth performance.

Conclusions and application of findings: The incorporation of *Moringa oleifera* and *Carica papaya* leaf powders into rabbit feed significantly reduced coccidia oocyst excretion and improved growth performance without adverse effects. Therefore, we recommend that farmers incorporate 15% *Moringa oleifera* or *Carica papaya* leaves into rabbit diets. This incorporation rate could be a natural alternative for improving rabbit productivity and health.

Keywords: Feeding, coccidiosis, nutraceutical, growth.

INTRODUCTION

Rabbit farming (*Oryctolagus cuniculus*) plays an important socio-economic role in Burkina Faso, contributing to food security and the income of smallholder farmers (Ouedraogo et al., 2021; Delma et al., 2025). However, feeding remains a major challenge due to the

high cost of the compound feed. In addition, there is a high incidence of digestive diseases, particularly gastrointestinal parasitic infections (Traoré et al., 2018; Ouedraogo et al., 2021). Among these, coccidiosis is the main threat to poultry. Caused by protozoa of

the genus *Eimeria*, it mainly affects young rabbits during weaning (Djebouri and Naami, 2017; Dakouri *et al.*, 2021). It causes intestinal lesions that lead to diarrhoea, poor nutrient absorption, slowed growth, reduced average daily weight gain, and a deterioration in feed conversion ratio, which can even result in mortality (Licois and Marlier 2008). These constraints have led to the search for local and affordable alternatives to improve the profitability and sustainability of rabbit farming. Integrating local plant resources into rabbit feed is a promising avenue for optimizing zootechnical performance while reducing costs. Among these resources, *Moringa oleifera* and *Carica papaya*, two functional foods, stand out for their nutritional richness, medicinal properties, and availability in Burkina Faso (Delma *et al.*, 2025). *Moringa oleifera*, often called the "tree

of life," is known for its high protein, vitamin, mineral, and antioxidant content (Lopez-Rodriguez *et al.*, 2020, Haris and Ahmad, 2023; Shivanna *et al.*, 2024). *Carica papaya* is an important source of vitamins, digestive enzymes, and fibre. The use of these plants in rabbit feed can potentially improve growth, intestinal health, and feed efficiency. The main objective of this study was to evaluate the *in vivo* antiparasitic and nutritional efficacy of moringa (*Moringa oleifera* L.) and papaya (*Carica papaya* L.) leaf powder in rabbits (*Oryctolagus cuniculus*). The specific objective was to identify local dietary alternatives that are essential for improving weight gain and overall health of rabbits while contributing to the economic viability and sustainability of local agricultural systems.

MATERIALS AND METHODS

Study site: The experimental setup was carried out at the Animal Production and Health Research Laboratory at the Saria Research Station. The site is located 23 km east of Koudougou, the capital of the Boulkiemde Province and the Centre-West region, and 80 km northwest of Ouagadougou in Burkina Faso.

Biological material: The plant material consisted of *Moringa oleifera* and *Carica papaya* leaves collected in the commune of Koudougou (Burkina Faso), dried indoors at room temperature in the laboratory for two weeks, and then ground into powder in a mill. The animal material used consisted of 28 weaned rabbits aged 45–60 days, with an average live body weight (LBW) of 612.4 g.

Experimental protocol: The study was conducted in two distinct consecutive phases: a 10-day adaptation phase and a weekly data collection phase spanning 28 days for the parasitic effect and 56 days for the weight gain effect. A total of 28 rabbits (*Oryctolagus cuniculus* L.) aged between 45 and 60 days,

with an average live body weight (LBW) of 612.4 g, were placed in parallelepiped cages of appropriate dimensions, measuring 115 × 65 × 35 cm (length, width, and height). The cages were randomly arranged. The animals were divided into a completely randomized design into seven (7) groups of comparable weights: one group of four (4) animals corresponding to the control group and six (6) groups of four (4) animals corresponding to the six other rations. The experimental rations were distributed every day at 8 a.m., and drinking water was provided *ad libitum*. Every morning, the uneaten quantities were removed from the feeders and weighed for each animal, and the remaining water was emptied and replaced with fresh water. During the trial, seven (7) experimental rations were formulated from ordinary raw materials and powdered leaves from each plant. The rations formulated in this trial were control ration, RM5, RM10, RM15, RP5, RP10, and RP15, where *Moringa oleifera* (M) and *Carica papaya* (P) leaf meal was incorporated at rates

of 5%, 10%, and 15%, respectively, from a base mixture. The control ration consisted of 50% corn bran, 5% corn kernels, 20% rice bran, 2% cottonseed meal, 10% African locust bean flour, 10% peanut shells, and 2% vitamin-mineral concentrates.

Group (control) was fed the control ration;

Group 2 (RM5) was fed the ration containing 5% *Moringa oleifera* leaves;

Group 3 (RM10) was fed the ration containing 10% *Moringa oleifera* leaves;

Group 4 (RM15) was fed the ration containing 15% *Moringa oleifera* leaves;

Group 5 (RP5) was fed the ration containing 5% *Carica papaya* leaves;

Group 6 (RP10) was fed with the ration containing 10% *Carica papaya* leaves;

Group 7 (RP15) was fed a ration containing 15% *Carica papaya* leaves.

Antiparasitic activity on naturally infested subjects

Coproscopy: Evaluation of antiparasitic activity: Parasitological examinations were conducted at the INERA-Saria Animal Production Department laboratory. Faecal samples were collected weekly from each rabbit for four weeks. Samples were collected directly from the cages to avoid external contamination. For parasitological analysis, the McMaster method was used to quantify the number of parasite eggs per gram of faeces (EPG). This technique allows the counting of helminth eggs and coccidian oocysts (Hansen and Perry, 1994). Each sample was analysed in triplicate to ensure the reliability of the results. Parasite types were identified using an optical microscope based on the morphology of the eggs and oocysts. EPG data were recorded for each animal at each collection point, allowing the evolution of the parasite load to be monitored throughout the study.

RESULTS

Feeding nutritive value: Bromatological analysis revealed that the chemical

To obtain the total number of oocysts present in one gram of faeces, the following formula was applied:

$$N = \frac{n \times V}{0.3 \times P}$$

N: number of oocysts in one gram of faeces;

n: number of oocysts present in the two grids of the cell;

V: total volume of the dense solution used;

P: total weight of faeces;

0.3: total volume of the two cell grids (0.15 ml x 2).

Evaluation of the efficacy of antiparasitic activity:

$$Repg = \left(1 - \frac{T}{C}\right) \times 100,$$

The reduction rate in faecal egg excretion or the therapeutic efficacy of the experimental rations containing the leaves of the two plants was calculated using the following formula Coles et al., (1992) :

Where: Repg: reduction in the number of eggs per gram of faeces; T and C: arithmetic mean for the treated groups and the control group, respectively.

Statistical analysis: The collected data were entered and classified using Excel version 2013. The data were analysed using R software (R-Development-core-team, 2013). Analysis of variance (ANOVA) was performed. The Student Newman and Keuls test at a 5% threshold was used to separate variances when the analysis revealed a difference between the means. Graphs and tables were plotted using Excel version 2013 software.

composition of the feeds varied according to their type. The dry matter (DM) content of the

feeds used in the trial ranged from $94.39 \pm 0.021\%$ to $94.785 \pm 0.08\%$ (Table 1). Diets containing *Moringa oleifera* exhibited crude protein contents ranging from $11.310 \pm 1.32\%$ to $12.965 \pm 0.049\%$ (Table I). However, the control diet recorded the highest crude protein level. Diets based on *Moringa oleifera* showed significantly lower crude protein

contents compared to diets formulated with *Carica papaya* leaf powder and the control diet. Bromatological evaluation of the different experimental diets highlighted significant differences ($p < 0.05$) in dry matter (% DM), ash, crude fibre, crude protein, and acid detergent fibre, depending on the level of incorporation of moringa or papaya leaves.

Table 1: Nutritive value of ration (in % DM)

	DM (%)	Ash (%)	Crude fibre (%)	CP (%)	ADF (%)	ADL (%)
RM10	94.53 ± 0.06^b	8.15 ± 0.52^b	14.57 ± 0.12^c	11.3 ± 1.33^{ab}	18.8 ± 0.66^b	4.3 ± 0.66^a
RM15	94.39 ± 0.02^c	8.26 ± 0.18^b	16.83 ± 0.5^a	12.97 ± 0.05^a	20.88 ± 0.95^a	4.4 ± 0.75^a
RM5	94.61 ± 0.04^{ab}	7.85 ± 0.13^b	15.90 ± 0.15^{ab}	10.435 ± 0.02^b	20.75 ± 0.39^b	4.5 ± 0.43^a
RP10	94.69 ± 0.01^{ab}	9.3 ± 0.1^a	16.09 ± 0.15^a	10.88 ± 0.53^b	20.3 ± 0.21^{ab}	5.14 ± 0.29^a
RP15	94.79 ± 0.08^a	9.4 ± 0.03^a	15.82 ± 0.41^{ab}	11.3 ± 0.07^{ab}	19.9 ± 0.11^{ab}	4.8 ± 0.24^a
RP5	94.7 ± 0.02^{ab}	8.9 ± 0.1^a	14.97 ± 0.4^{bc}	10.8 ± 0.47^b	19.9 ± 0.16^{ab}	4.9 ± 0.6^a
Control	94.7 ± 0.11^{ab}	8.04 ± 0.14^b	16.44 ± 0.43^a	12.99 ± 0.13^a	20.3 ± 0.46^{ab}	5.45 ± 0.21^a
p-value	0,0039	0,0009143	0,002939	0,0127	0,06144	0,3408

Values marked with different letters a, b, c, d, e, f, g in the same column are significantly different at the 5% threshold (p); RM10 = ration containing 10% moringa; RM15 = ration containing 15% moringa; RM5 = ration containing 5% moringa; RP10 = ration containing 10% papaya; RP15 = ration containing 15% papaya; RP5 = ration containing 5% papaya

DM: dry matter; CP: Crude protein; ADF: acid detergent fiber; ADL = acid detergent lignin

Effect of *Moringa oleifera* and *Carica papaya* leaf powder on the reduction rate of oocysts in naturally infested rabbits: The curves in Figures 1 and 2 illustrate the reduction rates of coccidian egg excretion levels per experimental batch. At the end of the trial, the reduction in excretion was significantly different ($P > 0.05$) between the control and different treated groups. Quantitative coproscopic analysis performed before treatment on day (D0), revealed that the different groups excreted eggs throughout the trial, with marked variability. Following treatment, coccidian egg excretion in the groups fed a diet based on different plant leaves was significantly reduced, almost to the point of disappearance, whereas coccidian

egg excretion increased in the control group. These results indicate that *Moringa oleifera* and *Carica papaya* leaves reduced coccidian oocyst excretion in the treated rabbits, regardless of the incorporation rate. The groups fed rations containing *Moringa oleifera* leaf powder showed a reduction in egg excretion, ranging from 750 ± 687.38 (RM15) to 16.67 ± 28.87 (RM10) on day 28 (D28). For groups fed rations containing *Carica papaya* leaf powder, the reduction in egg excretion ranged from 16.667 ± 28.87 (RP15) to 1166.67 ± 340.34 (RP5) on day 28. Furthermore, from days 21 to 28, no significant differences ($P > 0.05$) were observed between the different treatment groups (Table 2).

Table 2 : Reduction rate in coccidian egg excretion levels per experimental group

Ration	Oocysts of coccidia				
	Day 0	Day 7	Day 14	Day 21	Day 28
Control	2550 ± 217.94 ^d	4000 ± 180.28 ^d	5150 ± 785.81 ^a	12800 ± 2563.2 ^a	6300 ± 2338.8 ^a
RM5	17366.67 ± 5217.84 ^c	1850 ± 1050 ^f	1416.67 ± 748.89 ^c	166.67 ± 160.73 ^c	300 ± 259.81 ^c
RM10	9416.67 ± 534.63 ^d	3250 ± 973.4 ^{de}	250 ± 86.6 ^c	333.333 ± 236.9 ^c	16.67 ± 28.87 ^c
RM15	13033.33 ± 2608.32 ^d	7000 ± 2737.24 ^b	2050 ± 396.86 ^b	516.67 ± 485.63 ^c	750 ± 687.39 ^c
RP5	13216.67 ± 510.7 ^d	9283.33 ± 3862.1 ^a	4600 ± 901.39 ^{ab}	3400 ± 1452.58 ^b	1166.67 ± 340.4 ^b
RP10	76000 ± 3012.89 ^a	2033.33 ± 1184.6 ^{ef}	400 ± 229.13 ^c	83.33 ± 28.87 ^c	450 ± 150 ^c
RP15	50400 ± 6973.7 ^b	5216.67 ± 225.4 ^c	800 ± 229.13 ^c	1133.33 ± 596.2 ^c	16.67 ± 28.87 ^c
p-value	0.004	0.01	0.01	0.01	0.01

Values marked with different letters a, b, c, d, e, f, g in the same column are significantly different at the 5% threshold (p); RM10 = ration containing 10% moringa; RM15 = ration containing 15% moringa; RM5 = ration containing 5% moringa; RP10 = ration containing 10% papaya; RP15 = ration containing 15% papaya; RP5 = ration containing 5% papaya

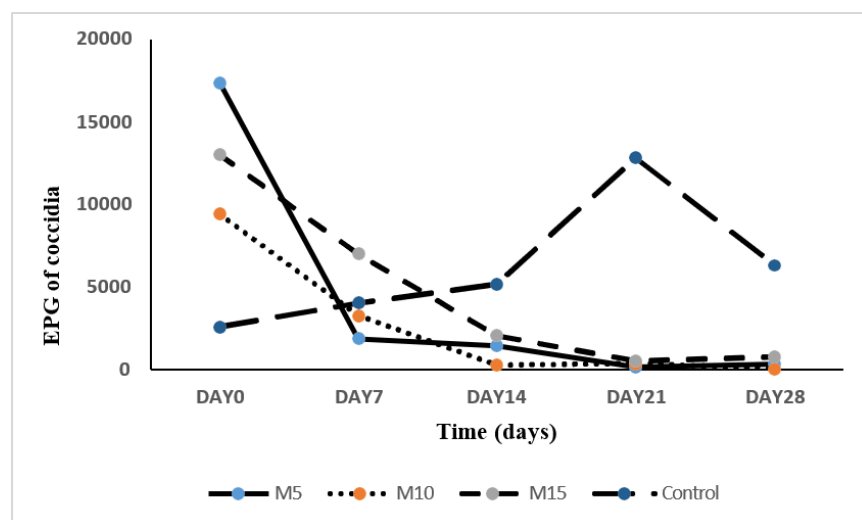


Figure 1: In vivo effect of incorporating *Moringa oleifera* leaf powder into the pelleted feed ration of rabbits on the excretion of coccidian oocysts. EPG = Number of eggs (or oocysts) per gram of faeces

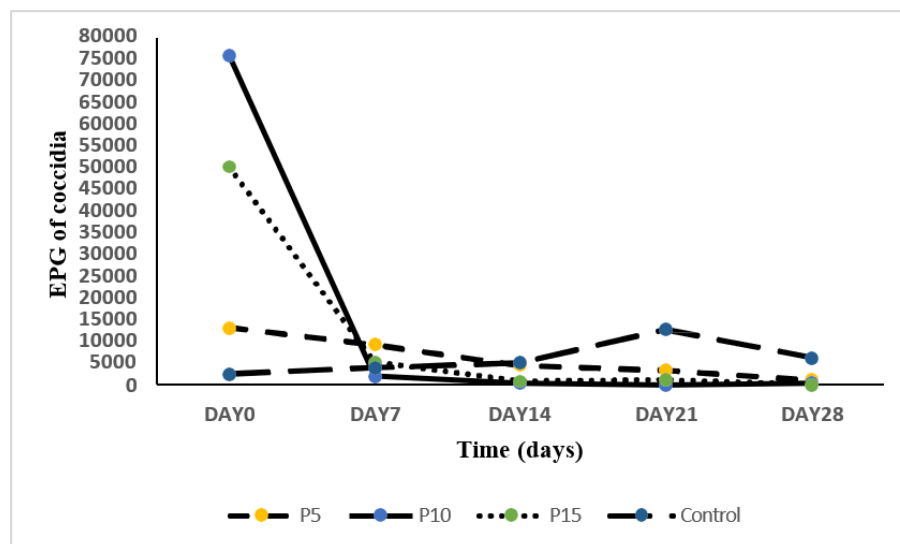


Figure 2: *In vivo* effect of incorporating *Carica papaya* leaf powder into the pellet feed ration of rabbits on coccidian oocyst excretion. EPG = Number of eggs (or oocysts) per gram of faeces

The effectiveness of treatments with leaf powder from both plants on coccidian oocyst excretion: The efficacy of treatments with leaf powders from both plants on coccidian oocyst excretion is summarized in Table 3. The antiparasitic efficacy, expressed as a percentage reduction in oocysts, exceeded 95% from the 21st day onwards in most groups treated with *Moringa oleifera*. For *Carica papaya*, this efficacy showed

more variation depending on the incorporation rate, ranging from 22% to 99.9% on the 21st day and 74% to 100% on the 28th day. The control groups showed negative values, indicating no effect and an increase in the parasite load. These results highlight the high efficacy of leaf powders as natural antiparasitic agents against coccidiosis in rabbits.

Table 3: Antiparasitic efficacy

Ration	Day 7	Day 14	Day 21	Day 28
Control	-57.21 ± 6.26	-103.4 ± 40.4	-399.63 ± 67.1	-143.25 ± 67.83
RM5	87.97 ± 8.53	90.13 ± 8.67	98.73 ± 1.57	98.34 ± 1.12
RM10	65.03 ± 12.04	97.33 ± 0.96	96.55 ± 2.26	99.82 ± 0.31
RM15	47.44 ± 10.15	84.26 ± 0.11	95.74 ± 4.58	93.83 ± 6.48
RP5	29.02 ± 31.09	65.18 ± 6.98	73.99 ± 11.83	91.14 ± 2.79
RP10	97.33 ± 1.53	99.48 ± 0.28	99.89 ± 0.04	99.41 ± 0.18
RP15	89.5 ± 1.65	98.44 ± 0.25	97.77 ± 1.11	99.97 ± 0.05

RM10 = ration containing 10% moringa; RM15 = ration containing 15% moringa; RM5 = ration containing 5% moringa; RP10 = ration containing 10% papaya; RP15 = ration containing 15% papaya; RP5 = ration containing 5% papaya

Effect on weight gain: The effect of the experimental rations on weight gain is illustrated by the curves and straight lines in Figures 3 and 4, respectively. The results of this study revealed that incorporating Moringa

and papaya leaves into the diet had no negative effect on the weight gain of young rabbits. The highest weight gain was observed in rabbits in group RM15 (751 ± 206.93 g), which was a significant improvement ($p =$

0.01) compared to the other groups, particularly the control group, which had the lowest weight gain (215.33 ± 86.95 g). The overall results suggested that the incorporation of *Moringa oleifera* leaf meal,

even at different rates (5%, 10%, and 15%), as well as papaya leaves (5%, 10%, and 15%), had a beneficial effect on the weight gain of rabbits.

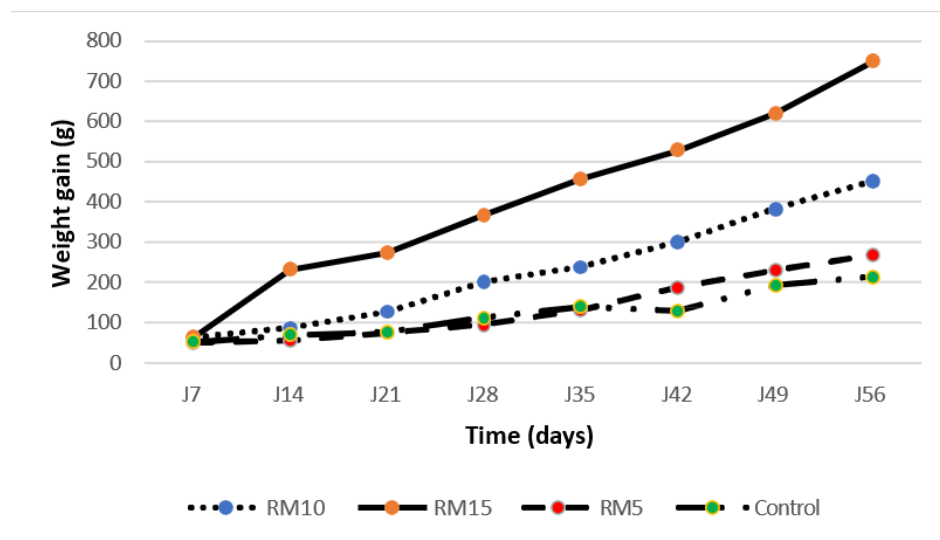


Figure 3: Effect of incorporating *Moringa oleifera* on weight gain

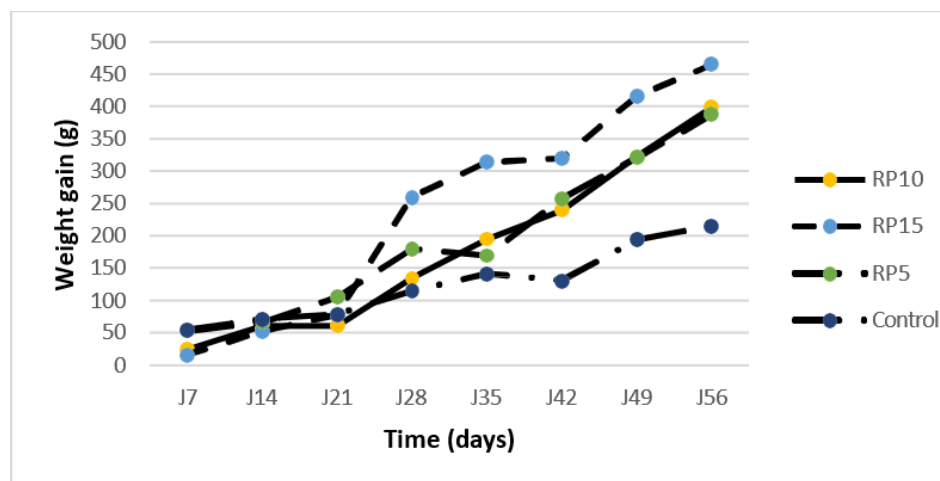


Figure 4: Effect of incorporating *Carica papaya* on weight gain

DISCUSSION

The high crude protein contents in moringa-based diets corroborate the findings of Melesse *et al.* (2013) and Ndofor-Foleng *et al.* (2019), who emphasized the richness of *Moringa oleifera* in digestible proteins, essential amino acids, and minerals, making this plant particularly suitable for monogastric feeding. The results of this experiment

showed that adding *Moringa oleifera* and *Carica papaya* leaf powders to the diet of young rabbits significantly reduced coccidian oocyst excretion in the different treatment groups. This reduction, observed gradually from the 7th day after administration, increased until it reached near-zero levels on day 28 in certain groups, notably RM10 and

RP15. In contrast, the control group showed a constant increase in oocyst excretion, indicating the absence of any antiparasitic effect in conventional non-enriched rations. Our results are consistent with those reported by Honvou *et al.* (2017), who observed control of oocyst infestation in rabbits after adding *Moringa oleifera* leaf granules at rates of 10 to 15% to commercial feed. This trend is also supported by the observations of Al-Massad *et al.* (2018), who demonstrated that this dose reduced oocyst excretion in rabbits infected with *Eimeria spp.* by more than 95%. Pedraza-Hernández *et al.* (2021) demonstrated that the hydroalcoholic extract of *Moringa oleifera* leaves, used as a feed additive, showed significant anthelmintic activity ($P = 0.002$) against various nematodes. Research conducted by Konmy *et al.* (2020) has shown that the leaves contain large groups of chemical compounds with antiparasitic properties, such as total phenols (384.09 mg GAE/50 g), flavonoids (0.019 mg RE/50 g), tannins (9.60×10^{-6} mg CE/50 g), saponosides, and quinone derivatives. For *Carica papaya*, the efficacy was also remarkable, particularly in the RP15 group, where a reduction in EPG comparable to that of the RM10 group was observed. This anticoccidial action is attributed to proteolytic enzymes such as papain, as well as tannins and alkaloids present in papaya leaves (Choudhary *et al.*, 2025; Pedraza-Hernández *et al.*, 2021) which inhibit oocysts, in accordance with the study by Sofowora *et al.* (2017). The RP10 group also showed a significant reduction in EPG levels. The RP5 group showed an initial increase in the number of eggs per gram of faeces after seven days, followed by a partial decrease after twenty-eight days. This indicates that the low dose used may not only be insufficient to achieve a therapeutic effect but may also disrupt the balance of the intestinal flora, which could promote the development of parasites. In the control group, a steady and

marked increase in EPG was observed, clearly demonstrating that standard diets are unable to control coccidiosis. The observed antiparasitic efficacy can be attributed to two factors. First, the direct action of secondary plant compounds interferes with sporulation and oocyst maturation (Oyagbemi *et al.*, 2021). Second, the immunomodulatory properties of *Moringa* and *papaya* strengthen local intestinal immunity.

Data analysis showed that *Moringa oleifera* and *Carica papaya* leaf powders were effective in reducing coccidian oocyst excretion in young rabbits. From day 21 onwards, the groups receiving these treatments showed a significant reduction in excretion compared to the control group, in which the number of eggs per gram of faeces increased substantially. This observation confirms the pronounced anticoccidial effects of these two plants. This downward trend was observed throughout the study period and was evaluated according to the method of Coles *et al.* (1992) with different incorporation rates. The antiparasitic activity of *Moringa oleifera* was particularly noteworthy, with a reduction of more than 95% in EPG from the 21st day for all doses tested, reaching as high as 99.8% for the 10% dose on the 28th day. These results are consistent with those of Konmy *et al.* (2020), who observed efficacies of 97.58% and 97.57% in rabbits infected with *Eimeria* after supplementation with *Moringa* (5%, 10%, and 15% incorporation) on coccidian oocysts. In addition, other authors Fadunsin *et al.* (2013) evaluated the efficacy of *Moringa oleifera* on *Eimeria* in local chickens. Their results also showed a significant decrease in coccidian oocyst infestation in the gut. Diets enriched with *Carica papaya* were also highly effective, particularly at 10% and 15%, which achieved reductions of 99.9% and 100% on days 21 and 28, respectively. These results confirm the observations of Sofowora *et al.* (2017), who demonstrated the anticoccidial effect of

papaya leaf extracts in poultry and goats, with a reduction rate of over 95% after two weeks of treatment. In contrast, the low dose of 5% *Carica papaya* proved ineffective, with negative efficacy values in the early days, suggesting an initial counterproductive effect that may result from the disruption of the intestinal flora. The unfavourable trend in the control group, with negative efficacy rates, illustrates the lack of natural control by conventional diets Konmy *et al.* (2020). Regarding the effect on oocyst excretion, studies have shown a significant reduction in coccidian oocyst excretion in rabbits fed diets containing *Carica papaya* and *Moringa oleifera* leaf powder. Research conducted by Konmy *et al.* (2020) demonstrated that *Moringa oleifera* leaves contain major groups of bioactive compounds with antiparasitic properties, such as total phenols (384.09 mg GAE/50 g), flavonoids (0.019 mg RE/50 g), tannins (9.60×10^{-6} mg CE/50 g), saponosides, and quinone derivatives. The anticoccidial effect of *Carica papaya* leaves is attributed to proteolytic enzymes such as papain, as well as tannins and alkaloids present in the leaves (Choudhary *et al.*, 2025; Pedraza-Hernández *et al.*, 2021), which inhibit oocysts excretion. This reduction was observed independent of the incorporation rate, indicating antiparasitic activity. The overall results indicate that the incorporation of *Moringa oleifera* leaf meal, even at different rates (5%, 10%, and 15%), as well as papaya leaf meal (5%, 10%, and 15%), has a beneficial effect on the weight gain of rabbits.

CONCLUSION AND APPLICATION OF RESULTS

This comparative study evaluated the incorporation of *Moringa oleifera* and *Carica papaya* leaf powders into the diet of domestic rabbits, focusing on their impact on weight gain, coccidiosis, and economic profitability. The results obtained are eloquent and highlight the potential of these natural food supplements. The incorporation of *Carica*

This notable improvement in weight gain in the RM15 group seems to be directly linked to the improved feed intake, confirming the findings of Ouédraogo *et al.* (2021), who established a positive correlation between feed intake and growth rate in rabbits. Furthermore, Dougnon *et al.* (2012) demonstrated that incorporating 10–15% moringa into rabbit feed does not negatively affect growth and may even improve weight gain. Selim *et al.* (2021) also observed improved weight gain with the incorporation of *Moringa* compared to the control ration. With regard to papaya leaves, our results are consistent with those of Coulibaly *et al.* (2024) in Burkina Faso, who noted a significant increase in rabbit weight with the addition of papaya leaves to their diet, up to 15%. Furthermore, Oloruntola *et al.* (2018) observed a significant improvement in the weight of rabbits fed a diet containing 10% papaya leaf. Jiwuba (2018) observed increased weight gain with incorporation rates of 15%, 30% and even 45% papaya leaf meal. In summary, adding up to 15% *Moringa oleifera* or *Carica papaya* leaves to rabbit feed is beneficial for their growth, with no negative effects observed. This highlights their potential as functional foods for sustainable animal production and human health. These results suggest that the two plants may have complementary applications in rabbit farming, *Moringa oleifera* for growth, and *Carica papaya* for parasitic health, although further research is needed to confirm these synergies.

papaya and *Moringa oleifera* leaf powders into rabbit feed had contrasting effects. *Carica papaya* reduces the excretion of coccidian oocysts, whereas *Moringa oleifera* significantly improves daily weight gain and growth performance. Although *Moringa* has a higher protein content and improves growth, papaya leaves exhibit antiparasitic activity,

suggesting complementary uses. With regard to coccidiosis, the incorporation of *Moringa oleifera* and *Carica papaya* leaf powder demonstrated a significant reduction in oocyst excretion in treated rabbits, reaching almost zero levels in some groups after 28 days, unlike the control group, where excretion increased. This antiparasitic efficacy was observed regardless of the incorporation rate, suggesting a beneficial effect of the bioactive compounds present in these medicinal plants, which are known as functional foods. In terms

of weight gain, the addition of these leaf powders proved beneficial for rabbit growth without causing any negative effects. Consequently, this study highlights the nutritional value of *Moringa oleifera* and *Carica papaya* leaves as functional food supplements. Their incorporation into rabbit feed offers a dual benefit, as it not only controls coccidiosis, a major challenge in rabbit farming, but also improves the growth performance and economic profitability of rabbit farms.

REFERENCES

- Al-Massad M, Al-Quraishy S, Abdel-Baky N, Dkhil M, 2018. Anticoccidial activity of *Moringa oleifera* leaf extract in rabbits. Journal of Ethnopharmacology 211: 174–179.
- Choudhary R, Kaushik R, Akhtar A, Manna S, Sharma J, Bains A, 2025. Nutritional, phytochemical, and antimicrobial properties of *Carica papaya* leaves: Implications for health benefits and food applications. Foods, 14, 154. DOI: <https://doi.org/10.3390/foods14020154>.
- Coles GC, Bauer C, Borgsteede F, Geerts S, Klei T, Taylor M, Waller P, 1992. Method for the detection of anthelmintic resistance in nematodes of veterinary importance. Veterinary Parasitology 44 : 35-44.
- Coulibaly A, Zongo R, Sawadogo J, 2024. Valorisation économique des fourrages non conventionnels dans l'alimentation du lapin. Revue Africaine de Zootechnie, 35(1) :47–56. DOI: <https://doi.org/10.4314/raz.v35i1.5>.
- Dakouri SA, Emanfo ASA, Kimsé M, Koné MW, Komoin-Oka AAC, Yapi YM, 2021. Prévalence des coccidioses chez les lapins domestiques (*Oryctolagus cuniculus*) élevés dans un environnement tropical humide : Bingerville, Côte d'Ivoire. Revue Ivoirienne des Sciences & Technologie 38 : 90-105.
- Delma BJ, Tianhoun DF, Yoda GML, Ouedraogo C, Ouattara N, Kabore A, 2025. Analysis of Ethnobotanical practices and knowledge of rabbit farmers in the treatment of gastrointestinal parasitoses in rabbits in the Northern Sudanian zone of Burkina Faso. International Journal of Advanced Research in Biological Sciences 12(8): 1-11. DOI: <http://dx.doi.org/10.22192/ijarbs.2025.12.08.001>
- Djebouri D. and Naami C, 2017. Contribution à l'étude de la coccidiose chez le lapin domestique « *Oryctolagus cuniculus* » dans la wilaya de Tizi Ouzou. Université Mouloud Mammeri, Faculté des Sciences biologiques et des sciences agronomiques département de biologie animal et végétale.
- Dougnon TJ, Aboh BA, Kpodékon TM, Honvou S, Youssao I, 2012. Effects of substitution of pellet of *Moringa oleifera* to commercial feed on rabbit's digestion, growth performance and carcass trait. Journal of Applied Pharmaceutical Science Vol. 2 (9): 015-019. DOI:

- 10.7324/JAPS.2012.2903.
- Hansen J. and Perry B, 1994. The epidemiology, diagnosis and control of helminth parasites of ruminants. ILRAD/ILCA, 2d édition, Addis Abéba, 171 pages.
- Haris Z. and Ahmad I, 2024. Evaluation of antioxidant-rich bioactive plant extracts with special reference to *Moringa oleifera* Lam. for their interference to bacterial quorum sensing and biofilm. *Phytomedicine Plus*, 4(2), 100511. DOI: <https://doi.org/10.1016/j.phyplu.2023.100511>
- Honvou SH, Aboh BA, Mensah SE, Akakpo RP, Atchade TG, Dougnon J, Mensah GA, 2017. Effet des granules de feuilles de *Moringa oleifera* sur les oocystes et la croissance pondérale des lapereaux au Bénin. *Journal de la Recherche Scientifique de l'Université De Lomé*, 19(4), 63–72. DOI: <https://doi.org/10.4314/jrsul.v19i4>.
- Jiwuba PC, 2018. Effect of pawpaw (*Carica papaya*) leaf meal on productive parameters of growing rabbits. *Agricultural Science and Technology*, Vol. 10, No 2: 102-106. DOI: <https://doi.org/DOI:10.15547/ast.2018.02.022>
- Konmy BBS, Olounladé PA, Doko-Allou S, Azando EVB, 2020. Evaluation of the activity of powder of leaves of *Moringa oleifera* on gastro intestinal parasites of the domestic rabbit (*Oryctolagus cuniculus*) in Southern Benin. *European Scientific Journal*, 16(30), 51-71. DOI: [10.19044/esj.2020.v16n30p51](https://doi.org/10.19044/esj.2020.v16n30p51)
- Licois D and Marlier D, 2008. Pathologies infectieuses du lapin en élevage rationnel. *INRA Productions Animales* 21: 257-268.
- Lopez-Rodriguez NA, Gaytán-Martínez M, de la Luz Reyes-Vega M, Loarca-Piña G, 2020. Glucosinolates and isothiocyanates from *Moringa oleifera*: Chemical and Biological Approaches. *Plant Foods for Human Nutrition*, 75(4), 447–457. DOI: <https://doi.org/10.1007/s11130-020-00851-x>
- Melesse A, Steingass H, Boguhn J, Rodehutsord M, 2013. In vitro fermentation characteristics and effective utilizable crude protein in leaves and green pods of *Moringa stenopetala* and *Moringa oleifera* cultivated at low- and midaltitudes. *Journal of Animal Physiology and Animal Nutrition* 97: 537–546. DOI: <https://doi.org/10.1111/j.1439-0396.2012.01294.x>
- Ndofor-Foleng HMOG, Iloghalu M, Egom A, Ikeh NE, Onodugo MO, Tchoupou E, Odo KOC, Okeke OC, 2019. Response of different breeds of rabbits to diets containing graded levels of *Moringa oleifera* leaf meal. *International Journal of Advanced Research in Biological Sciences*. 6(7): 84-92. DOI: <http://Dx.Doi.Org/10.22192/Ijarbs.2019.06.07.011>.
- Oloruntola O, Ayodele S, Adeyeye S, Ogunsipe M, Daramola O, Ayedun E, 2018. Effect of pawpaw leaf meal and multi enzyme supplementation in the diet on performance, digestibility, and oxidative enzyme status of rabbits. *The Journal of Basic and Applied Zoology* ,79:26 DOI: <https://Doi.Org/10.1186/S41936-018-0039-1>.
- Ouedraogo B, Nikiema ZS, Zoundi SJ, 2021. Cuniculture dans la zone périurbaine de Ouagadougou : situation actuelle et perspectives de son développement, *Revue Ivoirienne des Sciences & Technologie* 37 : 82-105
- Ouedraogo B. and Zoundi JS, 2021. Effets de

- l'incorporation de la farine de feuilles de *Moringa oleifera* sur les performances pondérales et les caractéristiques de la carcasse des poulets au Burkina Faso. *Revue Ivoirienne des Sciences & Technologie* 37: 282-299.
- Oyagbemi AA, Akinrinlola BR, Saka WT, 2021. Papaya leaf as an immunomodulator and liver protector in rabbits. *Veterinary Research Communications*, 45(3), 183–190.
- Pedraza-Hernández J, Elghandour M, Khusro A, Salem M, Camacho-Diaz L, Barbabosa-Pliego A, Salem A, 2021. Assessment on bioactive role of *Moringa oleifera* leaves as anthelmintic agent and improved growth performance in goats. *Tropical Animal Health and Production*, 53(2), 318. DOI : <https://doi.org/10.1007/s11250-021-02745-9>
- Selim S, Seleiman MF, Hassan MM, Saleh AA, Mousa, MA, 2021. Impact of dietary supplementation with *Moringa oleifera* leaves on performance, meat characteristics, oxidative stability, and fatty acid profile in growing rabbits. *Animals* 2021, 11, 248. DOI: <https://doi.org/10.3390/ani11020248>.
- Shivanna SK, Naik NL, Nataraj BH, Rao PS, 2024. *Moringa* marvel: navigating therapeutic insights and safety features for future functional foods. *Journal of Food Measurement and Characterization*, 18(6): 4940–4971. DOI: <https://doi.org/10.1007/s11694-024-02548-0>
- Sofowora A, Adebayo J, Okunlola O, 2017. Phytotherapy in small ruminants: use of *Carica papaya* in coccidiosis. *African Journal of Traditional, Complementary and Alternative Medicines*, 14(3), 134–140.
- Traoré B, Hien OC, Nikiéma AD, Bougouma/Yaméogo VMC, Belem AMG, 2018. Caractéristiques socioéconomiques de la cuniculture au Burkina Faso, *Science et technique, Sciences naturelles et appliquées Vols. 34 à 37 — 2015-2018*.